



PATIENT

Lilly Tucker

SPECIES

Canine

BREED

Sheepdog

SEX

MN

AGE

12 years

WEIGHT

51 #

INTERPRETED BY

Remo Lobetti, BVSc,
MMedVet (Med),
PhD, Dipl. ECVIM

**IMAGING
PERFORMED BY**

Lisa Bancroft, DVM

HOSPITAL NAME

Southside Veterinary
Hospital

REFERRING VET

Dr Kilpatrick

INVOICE

304195

DATE

5/6/23

PRESENTING CLINICAL SIGNS

History: Pancreatitis.

Physical Examination: N/A.

Urinalysis: N/A.

CBC: N/A.

Serum Biochemistry: N/A.

Radiographic Findings: N/A.

ULTRASONOGRAPHIC EXAMINATION OF THE ABDOMEN

Urinary System

Full urinary bladder with a normal thickness (0.2 cm) and appearance of the wall. Normal anechoic urine with no sediment or uroliths evident.

Normal trigone area, proximal urethra (0.4 cm), and iliac blood vessels.

Normal iliac lymph nodes. Ureters not visualized.

Normal renal size (left 6.5 cm, right 6.6 cm) with increased echogenic appearance, loss of cortico-medullary differentiation, normal pelvis, and irregular capsule. Multiple bilateral cortical cysts up to 0.9 cm in the left kidney and 1.6 x 1.9 cm in the right kidney.

Reproductive System

Small hypoechogenic prostate (0.8 cm).

Adrenal Glands

Normal shape, echogenic appearance, and position but plumb in size. Left 0.75 cm, right 0.74 cm.

Spleen

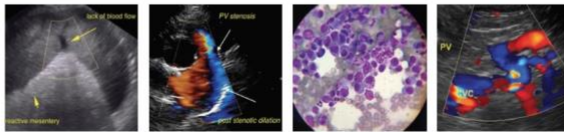
Normal size and echogenic appearance. Smooth homogenous parenchyma, regular curvilinear capsule, and normal vasculature. No inflammatory, neoplastic, infarction, or infiltrative changes evident.

Liver

Enlarged with rounded edges, increased echogenic appearance, some loss of portal markings, and regular curvilinear capsule. Focal isoechogenic nodule in the left medial lobe. No masses evident.

Gall bladder

Full containing normal anechoic bile. Small non-obstructive cholelith (0.7 cm) evident. Normal thickness and echogenic appearance of the wall. Normal bile duct.



PATIENT

Lilly Tucker

SPECIES

Canine

BREED

Sheepdog

SEX

MN

AGE

12 years

WEIGHT

51 #

INTERPRETED BY

Remo Lobetti, BVSc,
MMedVet (Med),
PhD, Dipl. ECVIM

**IMAGING
PERFORMED BY**

Lisa Bancroft, DVM

HOSPITAL NAME

Southside Veterinary
Hospital

REFERRING VET

Dr Kilpatrick

INVOICE

304195

DATE

5/6/23

Gastrointestinal

Normal appearance of the gastro-esophageal junction, duodenum, small intestine, ileo-cecal junction, and colon with no loss of layering, normal wall thickness (stomach 0.45 cm, duodenum 0.44 cm, jejunum 0.28 cm), and no distension of the lumen.

Pancreas

Normal size (left 0.9 cm, right 1.2 cm) and echogenic appearance. Regular capsule. Normal echogenic appearance of the mesentery and fat surrounding the pancreas.

Free Abdomen

No mesenteric lymphadenomegaly.
No ascites evident.

ULTRASONOGRAPHIC FINDINGS

Primary findings:

- Renal changes.
- Hepatopathy.
- Hepatic nodule.
- Bilateral adrenomegaly.

Secondary findings:

- Cholelith.

INTERPRETATION OF THE FINDINGS & FURTHER RECOMMENDATIONS

Etiologies for the kidneys would be age-related changes, chronic kidney disease, and bacterial nephritis.

Etiologies for the hepatopathy would be reactive, nodular hyperplasia, metabolic, vacuolar, hepatitis, and infiltrative neoplasia.

The most likely etiology for the hepatic nodule would be nodular regeneration with granuloma and neoplasia less likely differential diagnoses.

Etiologies for the adrenomegaly would be disease stress and emerging pituitary-dependent Cushing's disease.

Initial further assessment would be urinalysis, urine culture UPC (if sediment and culture negative), serum biochemistry, FNA cytology of the liver and hepatic nodule, and adrenal function testing (ACTH stimulation/LDDS test) if there are clinical and biochemical changes compatible with Cushing's disease.

Specific therapy would be dependent on an etiological diagnosis.



PATIENT

Lilly Tucker

SPECIES

Canine

BREED

Sheepdog

SEX

MN

AGE

12 years

WEIGHT

51 #

INTERPRETED BY

Remo Lobetti, BVSc,
 MMedVet (Med),
 PhD, Dipl. ECVIM

IMAGING PERFORMED BY

Lisa Bancroft, DVM

HOSPITAL NAME

Southside Veterinary
 Hospital

REFERRING VET

Dr Kilpatrick

INVOICE

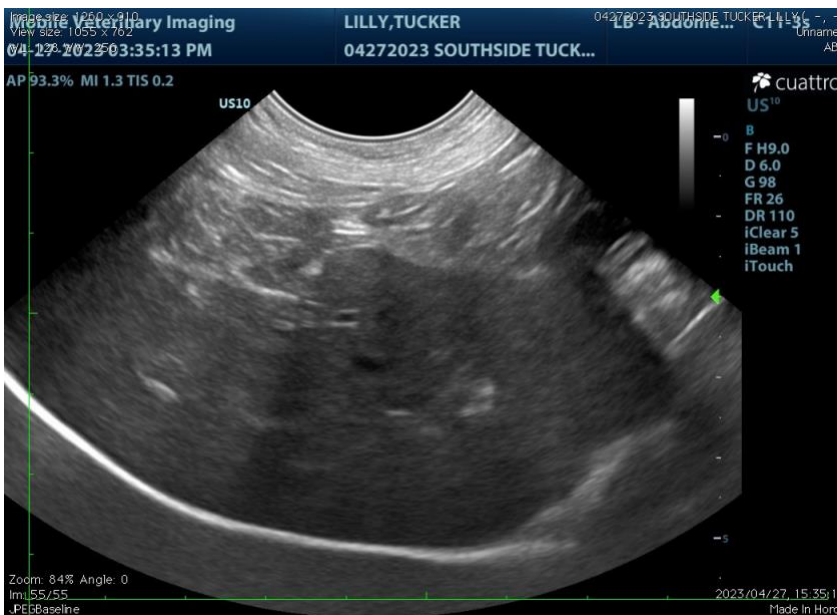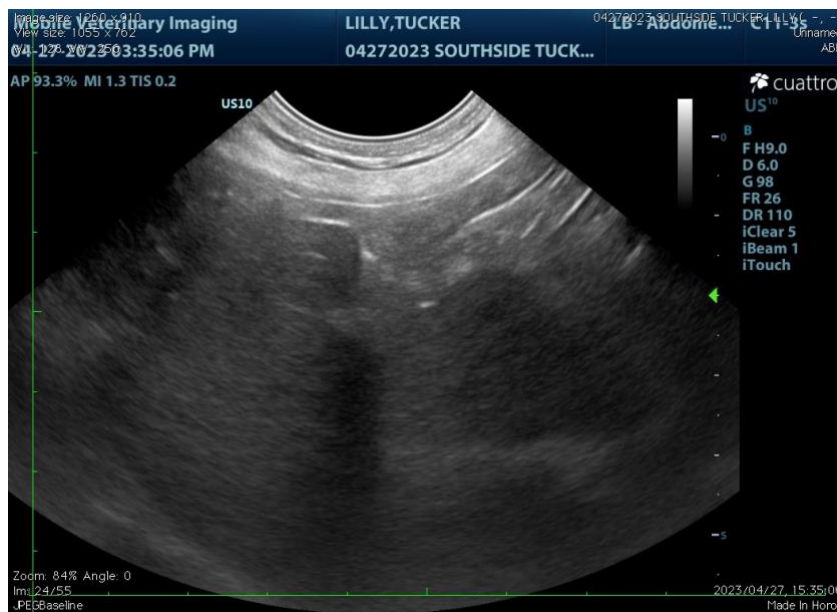304195

DATE

5/6/23

IMAGES

Liver





PATIENT

Left kidney

Lilly Tucker

SPECIES

Canine

BREED

Sheepdog

SEX

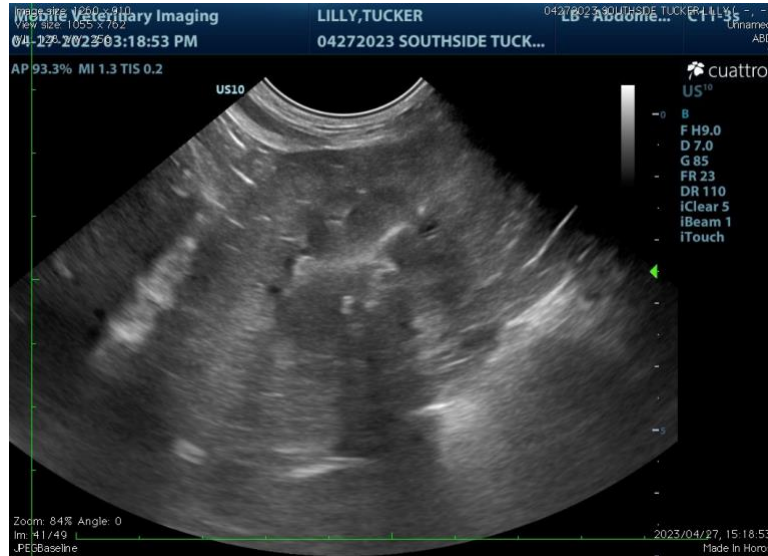MN

AGE

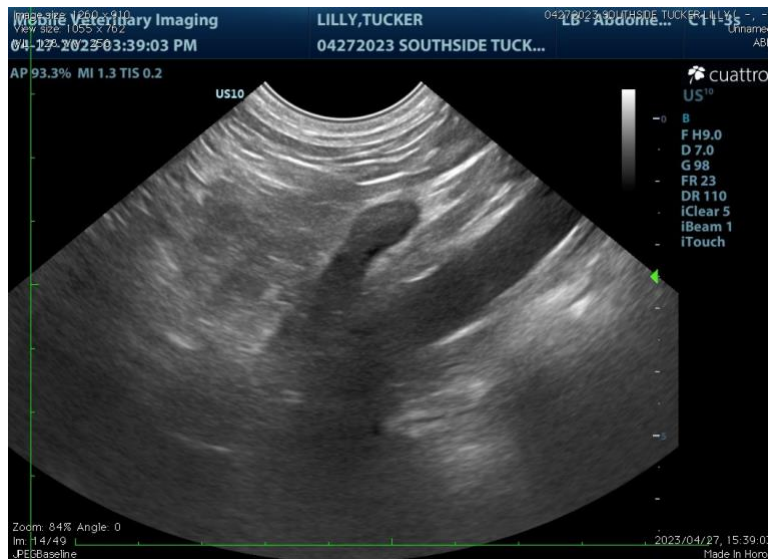12 years

WEIGHT

51 #



Right adrenal



INTERPRETED BY

Remo Lobetti, BVSc,
MMedVet (Med),
PhD, Dipl. ECVIM

IMAGING PERFORMED BY

Lisa Bancroft, DVM

HOSPITAL NAME

Southside Veterinary
Hospital

REFERRING VET

Dr Kilpatrick

INVOICE

304195

DATE

5/6/23

The information and recommendations provided are based on the images presented by the referring veterinarian. No evaluation can be communicated regarding pathology that was not visible in the image/video clips provided.

Thank you for this referral. If the clinical or image interpretation does not parallel your findings or if I can be of any further assistance please contact me.

Remo Lobetti, BVSc, MMedVet (Med), PhD, Dipl. ECVIM (Internal Medicine)
remo.lobetti@sonopath.com